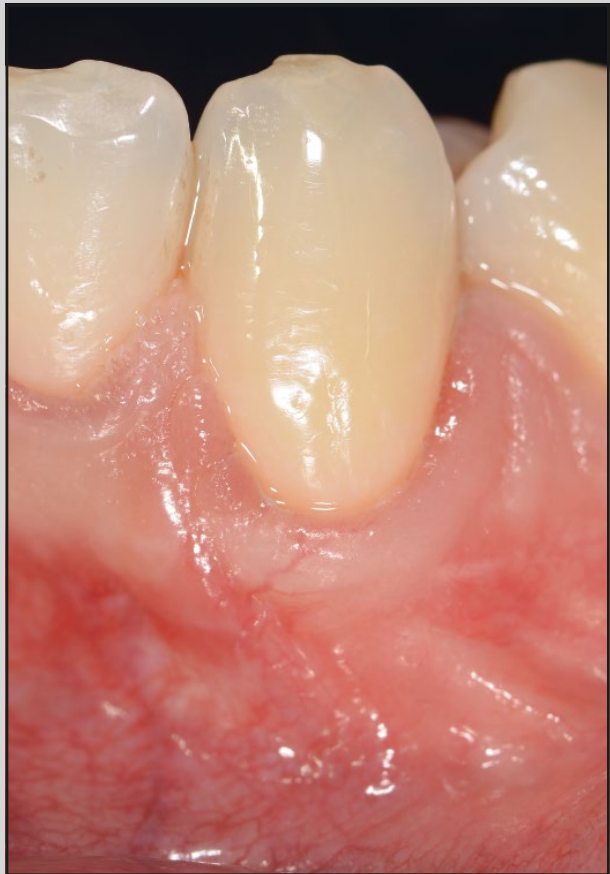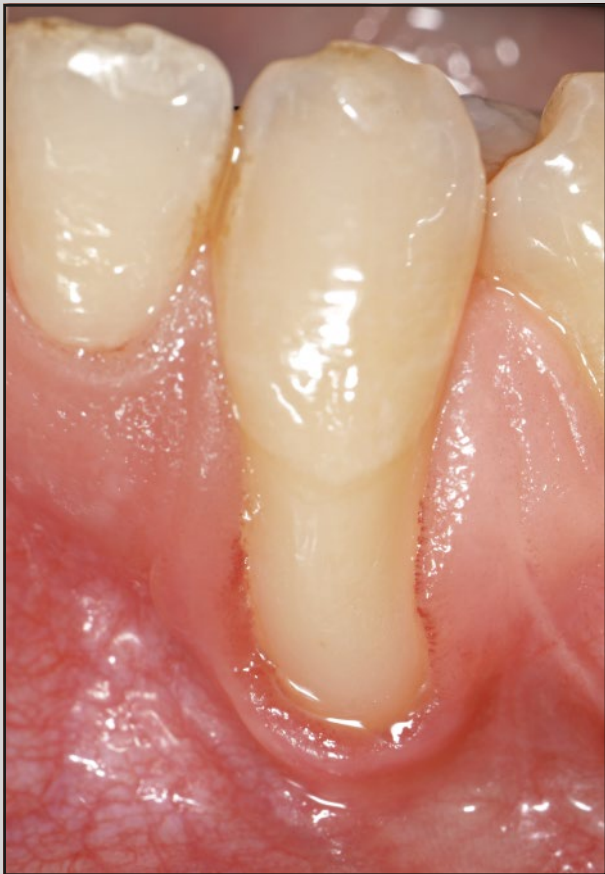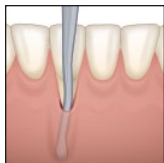




The Laterally Closed Tunnel for the Treatment of Deep Isolated Mandibular Recessions: Surgical Technique and a Report of 24 Cases



Anton Sculean, Prof Dr Med Dent, MS, Dr hc¹
Edward P. Allen, DDS, PhD²

Predictable coverage of deep isolated mandibular gingival recessions is one of the most challenging endeavors in plastic-esthetic periodontal surgery, and limited data is available in the literature. The aim of this paper is to present the rationale, the step-by-step procedure, and the results obtained in a series of 24 patients treated by means of a novel surgical technique (the laterally closed tunnel [LCT]) specifically designed for deep isolated mandibular recessions. A total of 24 healthy patients (21 women and 3 men, mean age 25.75 ± 7.12 years) exhibiting one single deep mandibular Miller Class I ($n = 4$), II ($n = 10$), or III ($n = 10$) gingival recession ≥ 4 mm were consecutively treated with LCT in conjunction with an enamel matrix derivative (EMD) and palatal subepithelial connective tissue graft (SCTG). The following clinical parameters were assessed at baseline and 12 months postoperatively: probing depth (PD), clinical attachment level (CAL), complete root coverage (CRC), mean root coverage (MRC), recession depth (RD), and keratinized tissue width (KTW). The primary outcome variable was CRC. The postoperative morbidity was low, and no complications, such as bleeding, infections/abscesses, or loss of SCTG, occurred. At 12 months, CRC was obtained in 17 of the 24 defects (70.83%), while in the remaining 7 defects RC amounted to 80% to 90% (in 6 cases) and 79% (in 1 case). Of the 17 defects exhibiting CRC, 12 were central incisors and 5 were canines. With respect to defect type, CRC was found in 3 of the 4 Miller Class I, 8 of the 10 Class II, and in 6 of the 10 Class III defects. Mean RD changed from 5.14 ± 1.26 mm at baseline to 0.2 ± 0.37 mm at 12 months, while MRC amounted to 4.94 ± 1.19 mm, representing 96.11% ($P < .0001$). Mean KTW increased from 1.41 ± 1.00 mm at baseline to 4.14 ± 1.67 mm ($P < .0001$) at 12 months, yielding a KTW gain of 2.75 ± 1.52 ($P < .0001$). No statistically significant changes in mean PD occurred following root coverage surgery (1.8 ± 0.2 mm at baseline and 2.1 ± 0.3 mm at 12 months). The present results suggest that the LCT is a valuable approach for the treatment of deep isolated mandibular Miller Class I, II, and III gingival recessions. *Int J Periodontics Restorative Dent* 2018;38:479–487. doi: 10.11607/prd.3680

¹Professor and Chairman, Department of Periodontology, School of Dental Medicine, University of Bern, Bern, Switzerland.

²Private Practice, Dallas, Texas, USA.

Correspondence to: Dr Anton Sculean, Professor and Chairman, Department of Periodontology, School of Dental Medicine, University of Bern, Freiburgstrasse 7, 3010 Bern, Switzerland. Email: anton.sculean@zmk.unibe.ch

©2018 by Quintessence Publishing Co Inc.

The displacement of the gingival margin apical to the cemento-enamel junction (CEJ) is defined as gingival recession (GR).^{1,2} Potential etiologic factors that have been associated with the development of gingival recessions are position and anatomy of teeth in the dental arch, bony dehiscences, thickness of the alveolar mucosa, excessive or incorrect tooth brushing, muscle pull, or orthodontic treatment.^{3–6} Depending on location (eg, in the maxillary or mandibular area), root surface exposure to the oral cavity may impair esthetics and lead to difficulties in performing adequate oral hygiene measures, facilitating the development of gingivitis and root caries. Findings from a retrospective case-controlled study indicate that active orthodontic treatment and retention may represent risk factors for the development of labial gingival recessions. The data also suggest that in orthodontically treated patients, mandibular incisors appear to be the most prone to development of gingival recessions.^{7,8} Conversely, the main indication to treat isolated mandibular gingival recessions is to increase soft tissue thickness and stability to facilitate plaque control and prevent further periodontal inflammation and breakdown or root caries.^{2,9}

Various surgical techniques have been proposed for the treatment of isolated mandibular recessions,

including the use of fully or partially epithelialized free gingival grafts (FGG) or subepithelial connective tissue grafts (SCTG) in conjunction with various types of flaps (eg, envelope, coronally or laterally positioned flap, double pedicle flap [DPF], or tunneling [TUN] alone or combined with laterally positioned pedicle flaps [LPPF]).¹⁰⁻¹⁶

In most of the described procedures, a split-flap approach was adopted for preparing the flap, tunnel, or envelope. However, especially in the mandibular anterior area, a split-flap approach may be difficult to perform and bears the risk of flap perforation and/or graft necrosis during the healing phase. To reduce these potential complications, a modification of the tunnel procedure, the modified coronally advanced tunnel (MCAT), consisting of a combined full- and partial-thickness pouch or tunnel/flap followed by coronal displacement, has been introduced.¹⁷ The clinical relevance of the MCAT for the treatment of isolated mandibular recessions was recently confirmed in a case series including 16 consecutively treated Miller Class I and II defects. At 12 months following reconstructive surgery, mean root coverage (MRC) amounted to 96.25%, while complete root coverage (CRC) was recorded in 12 of the 16 defects (75%).¹⁷ However, in deep isolated mandibular recessions located in the anterior area, tension-free coronal displacement of the tunnel flap can be extremely difficult and may result in decreased vestibular depth and flap dehiscence due to increased flap tension. Furthermore, most studies have only

evaluated treatment of Miller Class I and II isolated mandibular recessions, and limited information is available on the treatment of isolated mandibular Miller Class III defects. Therefore, new clinical approaches are warranted to predictably cover deep isolated anterior mandibular recessions and minimize the risk for postoperative complications caused by unfavorable anatomical situations.

The aim of this article is therefore to present the step-by-step procedure and the results obtained in a series of 24 patients treated by means of a novel surgical technique (eg, the laterally closed tunnel [LCT]) specifically designed for deep isolated mandibular Miller Class I, II, and III recessions.

Materials and Methods

Subject Selection

A total of 24 patients (3 men and 21 women, mean age 25.75 ± 7.12 years) presenting one deep (≥ 4 mm) isolated mandibular Miller Class I, II, or III recession¹⁸ located in the mandibular anterior area were included in the present cases series (Fig 1). All patients were nonsmokers and systemically and periodontally healthy. Professional tooth cleaning and individually tailored oral hygiene instructions were provided for each patient. Patients exhibited an adequate level of oral hygiene as evidenced by a full-mouth plaque score (FMPS) $< 25\%$ ¹⁹ and full-mouth bleeding score (FMBS) $< 10\%$.²⁰ Written informed consent was obtained from all patients.

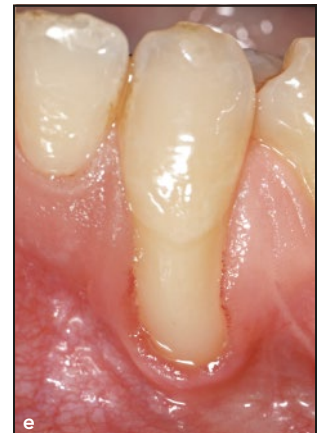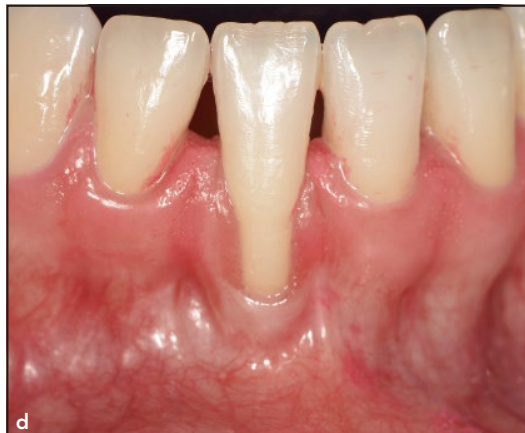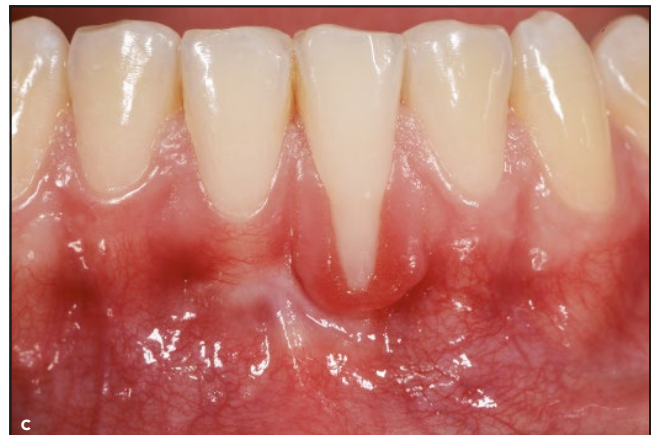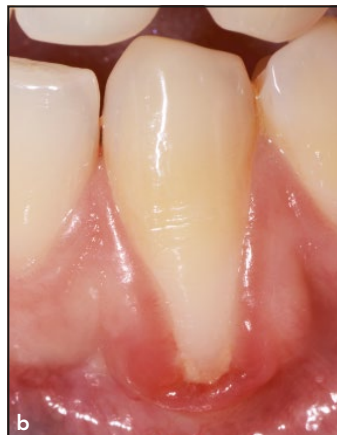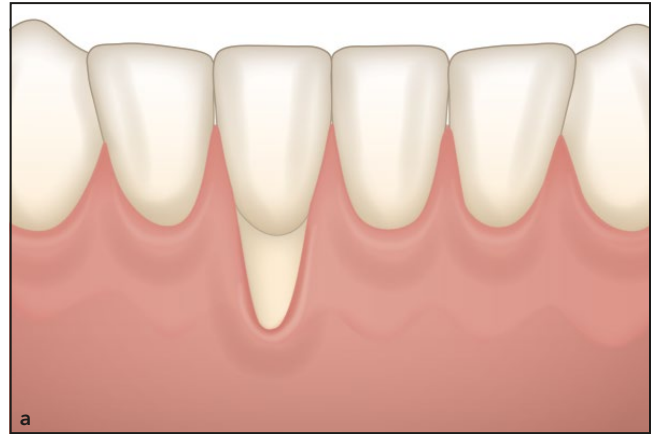
Surgical Approach

Patients were consecutively treated using the LCT technique by a single experienced clinician (A.S.). After local anesthesia, root planing of the exposed root surface was performed with Gracey curettes (Stoma). Subsequently, slightly beveled intrasulcular incisions were made using microsurgical blades (Micro Blades, Key Dent) and a mucoperiosteal pouch (tunnel) was prepared using specially designed tunneling instruments (Stoma) (Fig 2). No special attempt was made to remove the epithelium surrounding the margins of the pouch, since this was removed by means of the beveled intrasulcular incisions. The pouch was then mobilized apically beyond the mucogingival line and extended mesially and distally from the recession defect by undermining the facial surface of the interdental papillae (Fig 3). Muscles and collagen fibers inserting apically and laterally at the inner surface of the pouch were released using conventional and microsurgical blades (Micro Blades, Key Dent) and Gracey curettes (Stoma) until tension-free mesial and distal displacement of the pouch margins was obtained. Special attention was paid to avoid disrupting the interdental papillae or perforating the flap.

As a result of this procedure, the margins of the pouch could be approximated without tension mesially and distally to cover completely or cover the greater part of the exposed root surface (Fig 4).

Subsequently, a palatal SCTG 1 to 1.5 mm thick was harvested by means of the single incision technique and soaked for 5 to

Fig 1 (a) Preoperative situation of an isolated, deep Miller Class I to II recession. (b) Preoperative view of a deep Miller Class II recession located at the facial aspect of the mandibular left canine. Note the plaque accumulation and the inflammation of the soft tissue apical to the recession. (c) Preoperative view of a deep Miller Class II recession located at the facial aspect of the mandibular left central incisor. (d) Preoperative view of a Miller Class III recession located at the facial aspect of the mandibular right central incisor. (e) Preoperative view of an extremely deep Miller Class II recession located at the facial aspect of the mandibular left canine.



10 minutes in EMD (Emdogain, Straumann).^{21,22} Immediate closure of the donor site was performed using modified mattress sutures (5-0 Seralon, Serag-Wiessner).

After root surface conditioning with 24% ethylenediaminetetraacetic acid (EDTA) (PrefGel, Straumann) and copious rinsing with sterile saline solution to remove EDTA

residue, EMD was applied on the root surface by means of a sterile syringe. Using either single or mattress sutures, the SCTG was pulled and fixed mesially and distally at

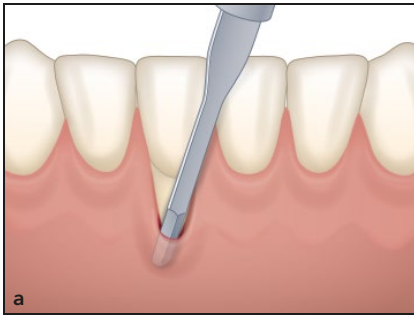


Fig 2 (a) Intrasulcular incision using a microsurgical blade. (b) Vertical preparation of the tunnel. (c) Lateral preparation of the tunnel. (d) Mobilization of the interdental papilla by means of a specially designed tunnel instrument.

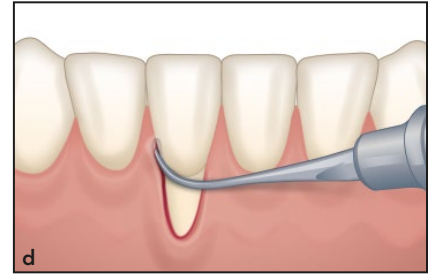
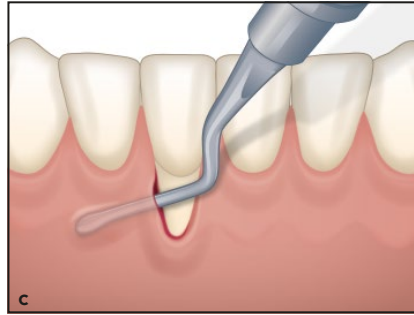
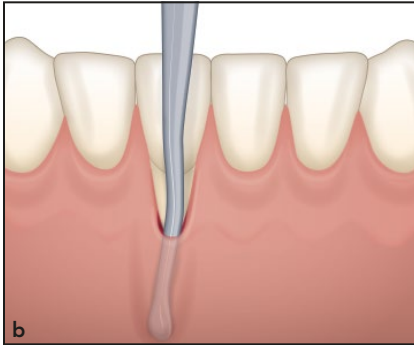


Fig 3 (a) The prepared tunnel. (b) Tunneled distal papilla at the mandibular left canine (case shown in Fig 1b). (c) Tunneled mesial papilla at the mandibular left canine (case shown in Fig 1b).

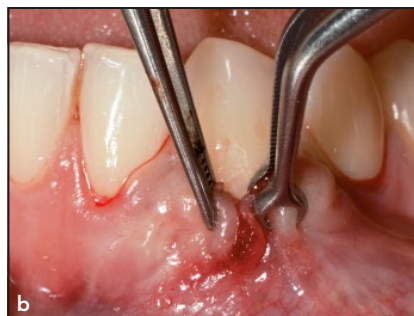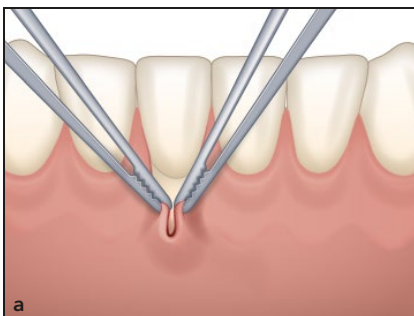
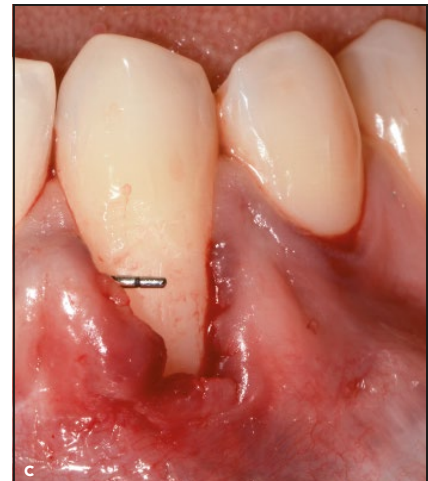
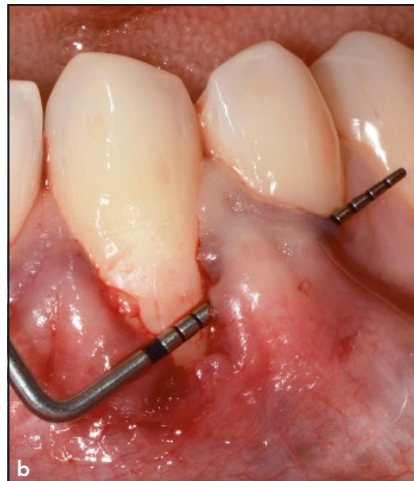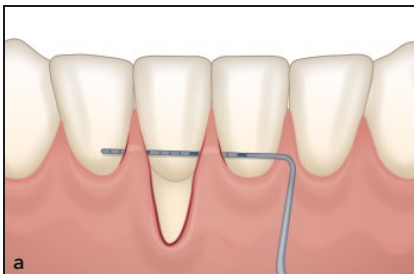


Fig 4 (a) Schematic drawing illustrating the tension-free lateral movement/adaptation of the soft tissue margins. (b) Tension-free lateral movement/adaptation of the soft tissue margins allowing complete recession coverage of tooth 33 (case shown in Fig 1b).

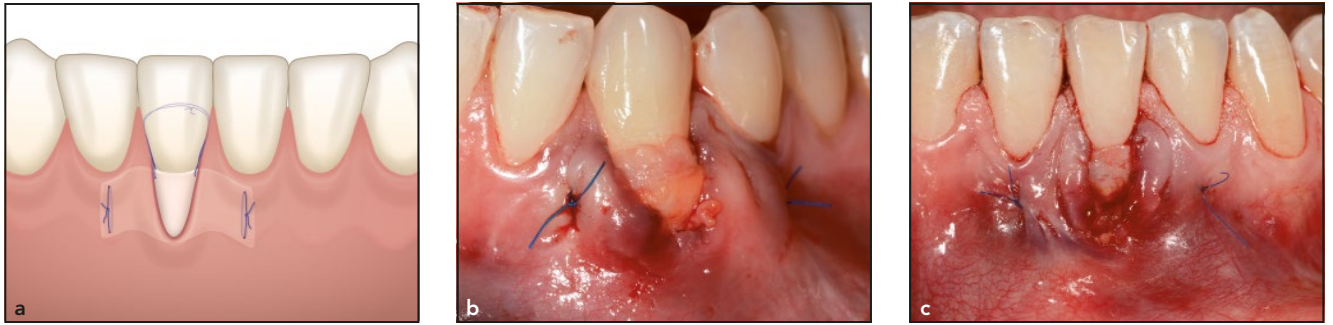


Fig 5 (a) Fixation of the connective tissue. (b) Sutured connective tissue graft in the tunnel and on the facial recession of the mandibular left canine (case shown in Fig 1b). (c) Sutured connective tissue graft on the facial recession of the mandibular left central incisor (case shown in Fig 1c).

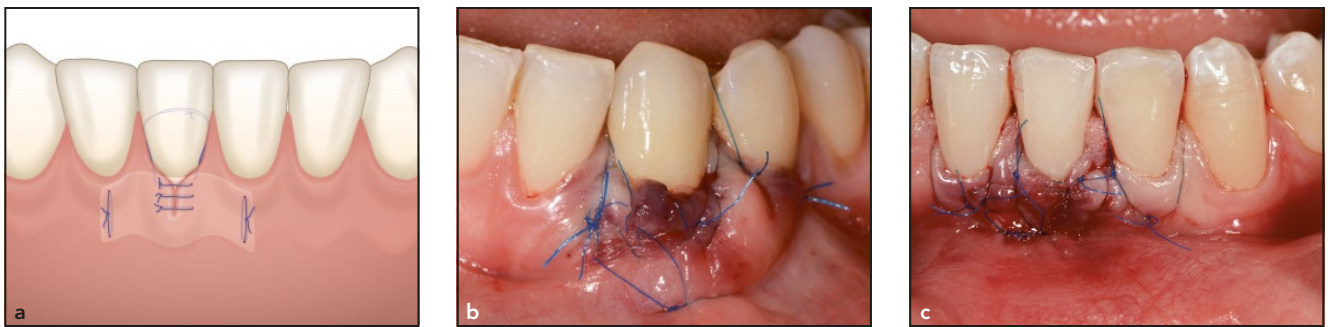

Fig 6 (a) Suturing of the tunnel margins by means of single sutures. (b) Closure of the tunnel by means of single sutures. Note the complete coverage of the CTG (case shown in Fig 1b). (c) Closure of the tunnel at the mandibular left central incisor (case shown in Fig 1c).

the inner aspect of the pouch. The graft was adapted to the CEJ by means of a sling suture (6-0 Seralon, Serag-Wiessner) (Fig 5). Finally, the margins of the pouch were pulled together over the graft and sutured with interrupted sutures to accomplish tension-free complete or partial coverage of the graft as well as the denuded root surface (Fig 6).

Postsurgically, patients were given analgesics (500 mg mefenamic acid [Mephadolor, Mepha Pharma] twice a day for 2 to 3 days) and antibiotics (1,000 mg amoxicillin and clavulanic acid [Augmentin, GlaxoSmithKline] for 7 days) to

prevent infection. Patients were not allowed to brush the surgical sites for 14 days postoperatively and were advised to use a 0.1% chlorhexidine-digluconate mouth-rinse (Chlorhexamed, GlaxoSmithKline) twice a day for 1 minute for the first 21 days postsurgery. Patients resumed tooth brushing 14 days after surgery. The palatal sutures were removed 7 days after surgery, while those from the treated teeth were removed 14 to 21 days postoperatively. At that time, patients were instructed in mechanical tooth cleaning of the surgical sites using an ultrasoft manual tooth-

brush (TePe Special Care) with the roll technique, gradually returning to regular oral hygiene habits at 1 month postsurgery. Recall appointments including professional supragingival tooth cleaning and individually oriented oral hygiene instructions were scheduled at 1, 3, 6, and 12 months postoperatively.

Clinical Assessments

The following clinical parameters were assessed at baseline and 12 months postoperatively: probing depth (PD), complete root coverage

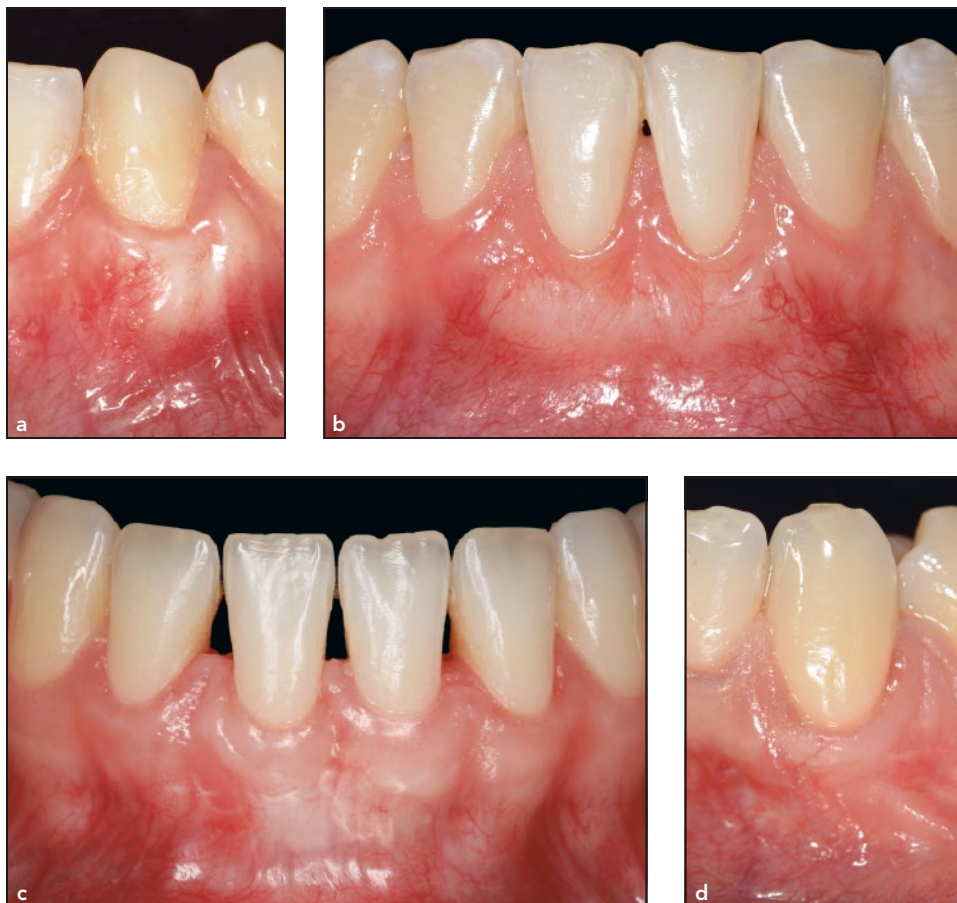

Fig 7 (a) At 12 months following reconstructive surgery, the mandibular canine demonstrates complete root coverage and an optimal tissue blending (case shown in Fig 1b). (b) Clinical view of the mandibular left central incisor demonstrating complete root coverage and a natural tissue texture at 12 months following reconstructive surgery (case shown in Fig 1c). (c) Clinical view of the mandibular right central incisor demonstrating complete root coverage (case shown in Fig 1d). (d) Treatment outcome at the mandibular left canine (case shown in Fig 1e). Complete root coverage and a natural tissue blending are evident.

(CRC), mean root coverage (MRC), recession depth (RD), and keratinized tissue width (KTW). KTW was measured with a periodontal probe (UNC-15, Hu-Friedy) as the distance between the gingival margin and the mucogingival line. The primary outcome variable was CRC (ie, 100% root coverage).

Statistical Analysis

Statistical analysis was performed using the commercially available software SPSS (SPSS Statistics, version 23, IBM). The primary outcome variable was CRC. Intragroup comparisons

between baseline and 12 months after therapy were determined with Wilcoxon test. Differences were considered statistically significant when the P value was $< .05$.

Results

In total, 24 patients (21 women and 3 men, mean age 25.75 ± 7.12 years) fulfilling the inclusion criteria were consecutively treated with LCT + EMD + SCTG. Of these, 19 teeth were central incisors and 5 were canines. Four recessions were classified as Miller Class I, 10 as Class II, and 10 as Class III.

Postoperative morbidity was low, and no complications such as bleeding, infections/abscesses, or loss of SCTG occurred. In 14 of the 24 defects, the tunnel did not completely cover the SGCT, leaving the coronal part of the graft exposed. However, graft necrosis was not observed in any of the defects, independent of the presence or absence of exposure.

At 12 months, CRC was obtained in 17 of the 24 defects, representing 70.83% of the defects. In the remaining 7 defects, recession coverage (RC) amounted to 80% to 90% in 6 cases and 79% in 1 case (Fig 7). Of the 17 defects exhibiting

CRC, 12 were central incisors and 5 were canines. CRC was obtained in 11 of the 14 defects showing graft exposure and in 6 of the 10 defects with complete graft coverage.

With respect to the defect type, CRC was found in 3 of the 4 Miller Class I, 8 of the 10 Class II, and 6 of the 10 Class III defects. Mean RD changed from 5.14 ± 1.26 mm at baseline to 0.2 ± 0.37 mm at 12 months, while MRC amounted to 4.94 ± 1.19 mm ($P < .0001$), representing 96.11% of the initial recession depth (Table 1). Mean KTW increased from 1.41 ± 1.00 mm at baseline to 4.14 ± 1.67 mm ($P < .0001$) at 12 months, yielding a KTW gain of 2.75 ± 1.52 ($P < .0001$) (Table 1). No statistically significant changes in mean PD occurred following root coverage surgery (1.8 ± 0.2 mm at baseline, 2.1 ± 0.3 mm at 12 months).

Discussion

The present case series is the first evaluation of a novel surgical technique that was specifically designed to predictably cover deep isolated anterior mandibular recessions. At 12 months after surgery, substantial recession coverage was obtained in all treated defects. Mean RD changed from 5.14 ± 1.26 mm at baseline to 0.2 ± 0.37 mm at 12 months, while MRC amounted to 4.94 ± 1.19 mm ($P < .0001$), representing 96.11% of the initial recession depth. CRC was obtained in 17 of the 24 defects, representing 70.83%. The finding that CRC was obtained not only in Miller Class I and II defects, but also

Table 1 Descriptive Results and Significance at 12 Months Compared to Baseline

Parameter	Mean \pm SD (mm)	Min (mm)	Max (mm)	P
RD baseline	5.14 ± 1.26	2.58	8.34	
RD 12 mo	0.2 ± 0.37	0	1.31	
MRC	4.94 ± 1.19	2.58	7.75	$< .0001^*$
KTW baseline	1.41 ± 1.00	0	3.7	
KTW 12 mo	4.14 ± 1.67	1.19	7.18	
KTW gain	2.75 ± 1.52	0	6.48	$< .0001^*$

Wilcoxon Signed Ranks test was used for analysis.

*Statistically highly significant ($P < .0001$).

RD = recession depth; MRC = mean root coverage; KTW = keratinized tissue width.

in the majority (6 out of 10) of the Class III defects highlights the clinical relevance of this technique for the treatment of deep isolated mandibular recessions located in the anterior area. In terms of obtained clinical improvements, the present findings compare well to those from a previous case series including 16 patients exhibiting single isolated mandibular Miller Class I or II recessions treated with the MCAT technique in conjunction with EMD and SCTG and demonstrating a MRC of 96.25% and CRC in 75% (12 out of the 16) of the defects.¹⁷

Nevertheless, the CRC obtained in the present case series was slightly lower than that measured in the previously mentioned report (70.83% vs 75%). This difference may be due to the fact that while the previous report evaluated only Miller Class I and II defects, the present case series also included Class III defects.

The present results also compare well to those reported by Harris et al¹⁴ using a tunneling procedure combined with SCGT. In that study, isolated and multiple Miller Class I

and II recessions at mandibular incisors were treated with either CAF + SCTG, double pedicle flap (DP) + SCTG, or a tunneling procedure (TUN) with a laterally positioned pedicle (LAT) (TUN-LAT + SCTG).¹⁴ Similar to the results obtained in the present study, the best outcomes were obtained with TUN-LAT + SCGT (MRC 97.2%) followed by DP + SCGT (MRC 96.7%) and CPT + CT (MRC 90.3%).

Other techniques, such as the use of partially epithelialized FGGs in conjunction with a coronally positioned flap or a modified tunnel, have been reported to lead to excellent outcomes in the treatment of isolated mandibular Miller Class I and II recessions.^{12,16}

In a randomized controlled clinical study, Zucchelli et al¹⁰ evaluated the treatment of isolated Miller Class I and II gingival recessions at mandibular incisors. Treatment was performed by means of CAF + SGCT with or without removal of labial submucosal tissue (LST). The results showed predictable recession coverage, while the additional removal of LST yielded a tension-free

flap, resulting in less graft exposure and statistically significantly better CRC (48% vs 88%). These results are difficult to compare directly to those obtained in the present study, which also included Miller Class III defects and canines. Nevertheless, both studies point clearly to the pivotal role of tension-free coronal mobilization of the soft tissues surrounding the recessions to obtain predictable CRC.

The importance of complete graft coverage to obtain CRC in mandibular anterior teeth is still unclear. While some studies report statistically significantly better CRC when the SCTG is completely covered,¹⁰ other studies, including the present case series, have failed to show any differences in the outcomes.^{12,15,16}

The ability to completely cover Miller Class III recessions has been evaluated only in a limited number of studies. Aroca et al²³ reported CRC in 38% following treatment of multiple adjacent Miller Class III recessions using MCAT combined with EMD and SCTG, while in a retrospective case series, Esteibar et al²⁴ found CRC in 47.11% of sites. Nart et al¹⁵ treated a total of 14 isolated mandibular Miller Class II and III recessions in 10 patients by means of CAF and SCTG. At 11.7 months following surgery, mean RC was $90.22\% \pm 12.36\%$ for all treated recessions. In Miller Class II defects, mean RC measured $94.04\% \pm 10.45\%$, while CRC was obtained in 5 (71.42%) out of 7 defects. In Class III recessions, mean RC amounted to $86.41\% \pm 13.70\%$, and CRC was obtained in 3 (42.85%) out of 7 defects.

Despite the better outcomes obtained in Class II defects compared with Class III, the statistical analysis failed to reveal any differences between the two groups.

In the present study, the CRC obtained in Miller Class III defects measured 60% (6 of the 10 defects), which is higher than the values reported in the previously mentioned studies (about 40%). The results obtained with the LCT technique in Miller Class I, II, and III defects clearly reflect the value of this surgical approach for the treatment of deep isolated mandibular recessions located in the anterior area. It must be kept in mind, however, that the outcomes are highly dependent on careful patient selection (ie, no smokers were included and all patients demonstrated a high level of oral hygiene).²⁵

An important aspect of this surgical approach is the wide mesiodistal and apical mobilization of the tunnel, which enables tension-free lateral movement of the flap margins to cover the graft and the recession. The tension-free lateral movement and the passive lateral closure of the tunnel margins may be advantageous in the treatment of isolated deep recessions located in areas with inserting frenula or shallow vestibule, which makes a coronal, tension-free advancement of the flap extremely difficult. Previous studies have provided evidence for the critical role of tension-free flap mobilization and suturing in root coverage procedures.^{26,27} However, the present case series has only evaluated the proposed technique in isolated mandibular defects, and

therefore no conclusions can be drawn about its potential use for treatment of multiple recessions.

Besides the tension-free flap preparation, the use of SCTG plays a key role in increasing flap thickness and blood clot stability and in providing the cells needed for soft tissue regeneration and keratinization.²⁸

The additional application of EMD is based on findings that indicated a positive effect on periodontal wound healing and regeneration through a wide variety of factors shown to be beneficial for root coverage procedures, such as cell proliferation and differentiation, biosynthesis of extracellular matrix, angiogenesis, and mineralization of cementum and bone, and by promoting periodontal regeneration (ie, formation of periodontal ligament, root cementum, and alveolar bone) and more stable clinical outcomes.²⁹ On the other hand, the added clinical value of EMD to SCTG is still unclear and remains to be evaluated in further studies.^{30,31}

Conclusions

The present results indicate that the LCT represents a predictable approach for the treatment of deep isolated mandibular Miller Class I, II, and III gingival recessions.

Acknowledgments

The authors reported no conflicts of interest related to this study.

References

- Armitage GC. Development of a classification system for periodontal diseases and conditions. *Ann Periodontol* 1999; 4:1–6.
- Wennström JL. Mucogingival therapy. *Ann Periodontol* 1996;1:671–701.
- Serino G, Wennström JL, Lindhe J, Eneroth L. The prevalence and distribution of gingival recession in subjects with a high standard of oral hygiene. *J Clin Periodontol* 1994;21:57–63.
- Daprile G, Gatto MR, Checchi L. The evolution of buccal gingival recessions in a student population: A 5-year follow-up. *J Periodontol* 2007;78:611–614.
- Susin C, Haas AN, Oppermann RV, Haugejorden O, Albandar JM. Gingival recession: Epidemiology and risk indicators in a representative urban Brazilian population. *J Periodontol* 2004;75:1377–1386.
- Lovegrove J, Leichter J. Exposed root surface: A review of aetiology, management and evidence-based outcomes of treatment. *N Z Dent J* 2004;100:72–81.
- Renkema AM, Fudalej PS, Renkema A, Kiekens R, Katsaros C. Development of labial gingival recessions in orthodontically treated patients. *Am J Orthod Dentofacial Orthop* 2013;143:206–212.
- Renkema AM, Fudalej PS, Renkema AA, Abbas F, Bronkhorst E, Katsaros C. Gingival labial recessions in orthodontically treated and untreated individuals: A case-control study. *J Clin Periodontol* 2013;40:631–637.
- Agudio G, Nieri M, Rotundo R, Franceschi D, Cortellini P, Pini Prato GP. Periodontal conditions of sites treated with gingival-augmentation surgery compared to untreated contralateral homologous sites: A 10- to 27-year long-term study. *J Periodontol* 2009;80:1399–1405.
- Zucchelli G, Marzadori M, Mounssif I, Mazzotti C, Stefanini M. Coronally advanced flap + connective tissue graft techniques for the treatment of deep gingival recession in the lower incisors. A controlled randomized clinical trial. *J Clin Periodontol* 2014;41:806–813.
- Cairo F, Nieri M, Pagliaro U. Efficacy of periodontal plastic surgery procedures in the treatment of localized facial gingival recessions. A systematic review. *J Clin Periodontol* 2014;41(suppl):s44–s62.
- Cortellini P, Tonetti M, Prato GP. The partly epithelialized free gingival graft (pe-fgg) at lower incisors. A pilot study with implications for alignment of the mucogingival junction. *J Clin Periodontol* 2012;39:674–680.
- De Angelis N, Yumang C, Benedicenti S. Efficacy of the lateral advanced flap in root-coverage procedures for mandibular central incisors: A 5-year clinical study. *Int J Periodontics Restorative Dent* 2015;35:e9–e13.
- Harris RJ, Miller LH, Harris CR, Miller RJ. A comparison of three techniques to obtain root coverage on mandibular incisors. *J Periodontol* 2005;76:1758–1767.
- Nart J, Valles C, Mareque S, Santos A, Sanz-Moliner J, Pascual A. Subepithelial connective tissue graft in combination with a coronally advanced flap for the treatment of Miller Class II and III gingival recessions in mandibular incisors: A case series. *Int J Periodontics Restorative Dent* 2012;32:647–654.
- Stimmelmayer M, Allen EP, Gernet W, et al. Treatment of gingival recession in the anterior mandible using the tunnel technique and a combination epithelialized-subepithelial connective tissue graft—A case series. *Int J Periodontics Restorative Dent* 2011;31:165–173.
- Sculean A, Cosgarea R, Stähli A, et al. The modified coronally advanced tunnel combined with an enamel matrix derivative and subepithelial connective tissue graft for the treatment of isolated mandibular Miller Class I and II gingival recessions: A report of 16 cases. *Quintessence Int* 2014;45:829–835.
- Miller PD Jr. A classification of marginal tissue recession. *Int J Periodontics Restorative Dent* 1985;5:8–13.
- O’Leary TJ, Drake RB, Naylor JE. The plaque control record. *J Periodontol* 1972;43:38.
- Ainamo J, Bay I. Problems and proposals for recording gingivitis and plaque. *Int Dent J* 1975;25:229–235.
- Hürzeler MB, Weng D. A single-incision technique to harvest subepithelial connective tissue grafts from the palate. *Int J Periodontics Restorative Dent* 1999;19:279–287.
- Lorenzana ER, Allen EP. The single-incision palatal harvest technique: A strategy for esthetics and patient comfort. *Int J Periodontics Restorative Dent* 2000;20:297–305.
- Aroca S, Keglevich T, Nikolidakis D, et al. Treatment of class III multiple gingival recessions: A randomized-clinical trial. *J Clin Periodontol* 2010;37:88–97.
- Esteibar JR, Zorzano LA, Cundin EE, Blanco JD, Medina JR. Complete root coverage of Miller Class III recessions. *Int J Periodontics Restorative Dent* 2011;31:e1–e7.
- Chambrone L, Chambrone D, Pustiglioni FE, Chambrone LA, Lima LA. The influence of tobacco smoking on the outcomes achieved by root-coverage procedures: A systematic review. *J Am Dent Assoc* 2009;140:294–306.
- Pini Prato G, Pagliaro U, Baldi C, et al. Coronally advanced flap procedure for root coverage. Flap with tension versus flap without tension: A randomized controlled clinical study. *J Periodontol* 2000;71:188–201.
- Pini Prato GP, Baldi C, Nieri M, et al. Coronally advanced flap: The post-surgical position of the gingival margin is an important factor for achieving complete root coverage. *J Periodontol* 2005;76:713–722.
- Sculean A, Gruber R, Bosshardt DD. Soft tissue wound healing around teeth and dental implants. *J Clin Periodontol* 2014;41(suppl):s6–s22.
- Miron RJ, Sculean A, Cochran DL, et al. Twenty years of enamel matrix derivative: The past, the present and the future. *J Clin Periodontol* 2016;43:668–683.
- Henriques PS, Pelegrine AA, Nogueira AA, Borghi MM. Application of subepithelial connective tissue graft with or without enamel matrix derivative for root coverage: A split-mouth randomized study. *J Oral Sci* 2010;52:463–471.
- Rasperini G, Rocuzzo M, Francetti L, Acunzo R, Consonni D, Silvestri M. Subepithelial connective tissue graft for treatment of gingival recessions with and without enamel matrix derivative: A multicenter, randomized controlled clinical trial. *Int J Periodontics Restorative Dent* 2011;31:133–139.